



Published in final edited form as:

*Am J Orthod Dentofacial Orthop.* 2010 November ; 138(5): 577–581. doi:10.1016/j.ajodo.2009.10.037.

## Dentofacial effects of bone-anchored maxillary protraction: A controlled study of consecutively treated Class III patients

Hugo De Clerck<sup>a</sup>, Lucia Cevidanes<sup>b</sup>, and Tiziano Baccetti<sup>c</sup>

<sup>a</sup> Private practice, Brussels, Belgium; adjunct professor, Department of Orthodontics, School of Dentistry, University of North Carolina, Chapel Hill

<sup>b</sup> Assistant professor, Department of Orthodontics, School of Dentistry, University of North Carolina, Chapel Hill

<sup>c</sup> Assistant professor, Department of Orthodontics, University of Florence, Florence, Italy; Thomas M. Graber Visiting Scholar, Department of Orthodontics and Pediatric Dentistry, School of Dentistry, University of Michigan, Ann Arbor

### Abstract

**Introduction**—In this cephalometric investigation, we analyzed the treatment effects of bone-anchored maxillary protraction (BAMP) with miniplates in the maxilla and mandible connected by Class III elastics in patients with Class III malocclusion.

**Methods**—The treated sample consisted of 21 Class III patients consecutively treated with the BAMP protocol before the pubertal growth spurt (mean age,  $11.10 \pm 1.8$  years) and reevaluated after BAMP therapy, about 1 year later. The treated group was compared with a matched control group of 18 untreated Class III subjects. Significant differences between the treated and control groups were assessed with independent-sample *t* tests ( $P < 0.05$ ).

**Results**—Sagittal measurements of the maxilla showed highly significant improvements during active treatment (about 4 mm more than the untreated controls), with significant protraction effects at orbitale and pterygomaxillare. Significant improvements of overjet and molar relationship were recorded, as well as in the mandibular skeletal measures at Point B and pogonion. Vertical skeletal changes and modifications in incisor inclination were negligible, except for a significant proclination of the mandibular incisors in the treated group. Significant soft-tissue changes reflected the underlying skeletal modifications.

**Conclusions**—Compared with growth of the untreated Class III subjects, the BAMP protocol induced an average increment on skeletal and soft-tissue advancement of maxillary structures of about 4 mm, and favorable mandibular changes exceeded 2 mm.

The literature reports a series of treatment approaches regarding orthopedic treatment in Class III malocclusion.<sup>1</sup> However, effective maxillary protraction remains limited to the deciduous or early mixed dentition.<sup>2</sup> Preliminary studies have indicated success of maxillary protraction in the late mixed or permanent dentition phase (ages, 10–12 years) with innovative treatment techniques that use bone anchors and Class III elastics.<sup>3,4</sup> The use of temporary anchorage devices in maxillary protraction has increased over recent years,<sup>3–8</sup> but they have not yet been assessed in controlled studies.

---

Reprint requests to: Hugo De Clerck, Kerkstraat 120, 1150 Brussels, Belgium; hugo.declerck@skynet.be.

The authors report no commercial, proprietary, or financial interest in the products or companies described in this article.

The purpose of this controlled clinical trial was to evaluate the effects of a treatment protocol for Class III malocclusion consisting of surgically placed mini-plates in both the maxilla and the mandible connected by Class III elastics (bone-anchored maxillary protraction, BAMP). Specifically, we assessed the active treatment effects in skeletal, dentoalveolar, and soft-tissue facial structures of consecutively treated patients, compared with growth changes in a matched control group of untreated Class III subjects.

## MATERIAL AND METHODS

The treated group comprised 21 consecutive patients with dentoskeletal Class III malocclusion treated by 1 operator (H.D.C.) with the BAMP technique. Success of therapy at the end of the observation period was not a determining factor for selection of patients, since the treated sample was collected prospectively.

At the initial observation (T1), all patients had Class III malocclusion in the mixed or permanent dentition characterized by a Wits appraisal of  $-1$  mm or less (mean,  $-4.8 \pm 2.8$  mm), anterior crossbite or incisor end-to-end relationship, and Class III molar relationship. All patients were of white ancestry, with a prepubertal stage of skeletal maturity according to the cervical vertebral maturation method (stage 1 or 2).<sup>9</sup> Eighteen of the 21 patients were still prepubertal at the end of treatment (T2) (stages 1–3), whereas 3 patients were in stage 4.

A control group of 18 untreated subjects with dentoskeletal Class III malocclusion was obtained from the Department of Orthodontics of the University of Florence in Italy. The control group matched the treated group as to type of dentoskeletal disharmony, skeletal maturation at each time point, sex distribution, and mean duration of observation intervals (Table I).

In the BAMP orthopedic protocol, in each patient, 4 miniplates were placed on the left and right infrazygomatic crest of the maxillary buttress and between the mandibular left and right lateral incisors and canines. Small mucoperiosteal flaps were elevated, and modified miniplates (Bollard, Tita-Link, Brussels, Belgium) were secured to the bone by 2 (mandible) or 3 (maxilla) screws (diameter, 2.3 mm; length, 5 mm).<sup>3</sup> The extensions of the plates perforated the attached gingiva near the mucogingival junction (Fig 1). Three weeks after surgery, the miniplates were loaded. Class III elastics applied an initial force of about 150 g on each side, increased to 200 g after 1 month of traction, and to 250 g after 3 months. The patients were asked to replace the elastics at least once a day and wear them 24 hours per day. In 14 patients, after 2 to 3 months of intermaxillary traction, a removable biteplate was placed in the maxillary arch to eliminate occlusal interference in the incisor region until correction of the anterior crossbite was obtained. The surgeons' and patients' experiences and problems with the plates were described by De Clerck et al.<sup>3</sup>

Cone-beam computed tomograms (CBCTs) were taken immediately after the placement of the miniplates at T1 and after approximately 1 year at T2. The scans were acquired by using an iCat machine (Imaging Sciences International, Hatfield, Pa) with a  $16 \times 22$ -cm field of view. The CBCTs were used to create synthetic lateral cephalograms with magnification of 7.5% (version 10.5, Dolphin Imaging & Management Systems, Chatsworth, Calif).<sup>10,11</sup> The enlargement factor of the control cephalograms was similar, and no correction was made for enlargement in the analysis of the films. All cephalograms were digitally traced by 2 examiners, using the Dolphin and Viewbox (version 3.1, dHal, Kifissia, Greece) softwares. The cephalometric measures selected were based on a previously described reference system traced through craniofacial stable structures, with the addition of orbitale (Or) to Vertical T (VertT), pogonion (Pg) to VertT, inclination of the incisors to their respective bases, Wits appraisal, maxillomandibular differential (Mx-Md diff), and a soft-tissue analysis with linear

distances from anterior nasal spine (ANS'), Point A (A'), upper lip (Ulip), lower lip (Llip), Point B (B'), and Pg' to VertT (Fig 2).<sup>9</sup>

Before the cephalometric analysis, 15 lateral cephalograms from subjects in the study were traced and measured at 2 times within a week by the same operator (T.B.). The intraclass correlation coefficients (ICC) indicated excellent intraobserver agreement of the repeated measurements (ICCs varied between 0.966 for the ML-SBL angle and 0.995 for the inclination of the maxillary incisor to NI). Linear measurement errors averaged 0.4 mm (SD, 0.8 mm), and angular measurement errors averaged 0.6° (SD, 0.6°).

### Statistical analysis

The homogeneity between the treated and control groups allowed for comparisons without annualizing the data. In an exploratory analysis by the Shapiro-Wilks test, the data showed normal distribution. Therefore, parametric statistics was applied. Significant differences between the cephalometric variables at T1 in the treated vs the control groups were tested with independent-sample *t* tests.

Descriptive statistics were calculated for all measures at T1 and T2 for the treated and control groups. T1 to T2 changes in both groups and statistical significance were assessed with paired *t* tests. We used SPSS software (version 12.0, SPSS, Chicago, Ill) for statistical analysis. Statistical significance was tested at  $P < 0.05$ ,  $P < 0.01$ , and  $P < 0.001$ . The power of the study was adequate ( $> 0.85$ ), calculated by using the mean values and standard deviations of A-VertT at an alpha of 0.05, for a clinically detectable difference of 2.5 mm.<sup>2</sup>

## RESULTS

The analysis of the facial characteristics in the control and treated samples at T1 (Table I) showed no statistically significant differences between the 2 groups, except for a smaller Co-Go and less buccal inclination of maxillary incisors in the treated group.

The changes between T1 and T2 (Table II) showed significant active treatment effects. In particular, both A-VertT and Co-A showed average improvements in the treated subjects over the controls of almost 4 mm. Orbitale advanced almost 3 mm more in the treated group, whereas pterygomaxillare (Ptm) advanced almost 2 mm more in the treated patients than in the controls. Significant restraining effects on mandibular growth were recorded in the BAMP group, both at B-point and Pg. Increases in total mandibular length were significantly smaller in the treated group (-2 mm). Intermaxillary skeletal variables had highly significant improvements, with an increase in the Wits appraisal of 6.7 mm, and an average reduction in the Mx-Md diff of -5.7 mm. A significant posterior relocation of the condylar region was shown by opening of the CoVertT angle in the treated group vs the controls (2°). Significant though small (about 1°) clockwise rotation of the palatal plane and counterclockwise rotation of the mandibular plane were found in the treated group. No between-group differences were found for anterior facial height. A significant upward-forward direction of condylar growth was assessed in the treated group compared with the controls (Co-Go-Me, about 4°).

Overjet and molar relationship improved significantly—3.8 and 4.8 mm in the treated vs control groups—with significant deepening of the incisor relationship (1.5 mm). No significant change was detected in the inclination of the maxillary incisors, whereas a significant proclination was recorded for the mandibular incisors in the BAMP group vs the controls (1.7°).

All maxillary soft-tissue variables showed significant improvements of about 4 mm vs the untreated controls, whereas improvements in the mandibular soft-tissue variables ranged between 1.7 and 2.6 mm.

## DISCUSSION

This study is the first investigation on the effects of Class III treatment with bone anchorage in a sample of adequate size for statistical comparisons. Specific features of the study were the following: (1) Class III subjects were treated consecutively in a prospective clinical trial, (2) a well-matched control group of untreated Class III subjects was used for comparisons, and (3) all subjects were prepubertal before treatment.

The use of skeletal anchorage in the maxilla for orthopedic Class III treatment has been reported previously but always combined with facemask therapy.<sup>5–8</sup> The lack of a need for extraoral appliances in this study might have favorably affected compliance to wear intermaxillary elastics.

The comparison of the cephalometric data from the experimental group with the untreated control group showed highly significant maxillary advancement (approximately 4 mm). This effect was not limited to the alveolar bone but extended up to the levels of the pterygomaxillary fissure and the orbital ridge as well. This suggests that the maxillary bone as a whole moved forward as a result of treatment. Mandibular changes were also significant, even though at a lesser extent with respect to the maxillary changes. Both posterior positional relocation of the condyle and anteriorly reoriented direction of growth of the condyle took place in the treatment group. The combination of the changes in both jaws resulted in marked improvement of the intermaxillary relationships.

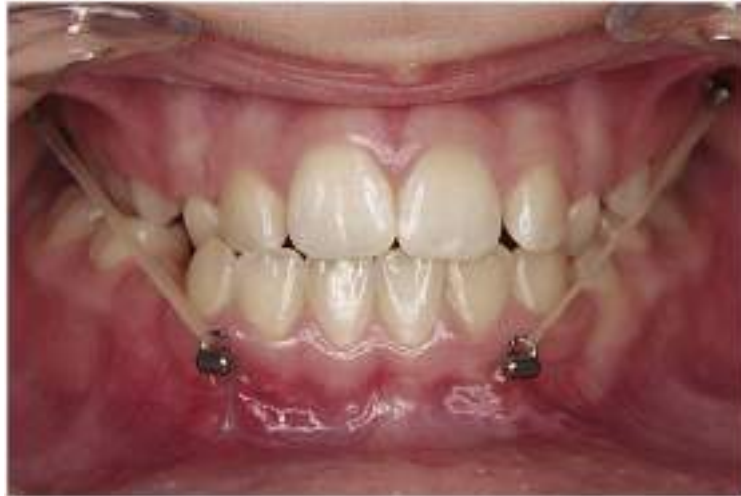The rotation of the mandibular and palatal planes of about 1° compared with the control sample was negligible. Counterclockwise rotation of the maxilla with a subsequent increase in the vertical dimension was not observed; on the contrary, Co-Go-Me closed by -4.1° compared with the control sample. Changes in dental inclination were minor too, since the protocol was strictly skeletal. An interesting amount of mandibular incisor proclination was observed in the treated group; this is an original finding with respect to any previous study on orthopedic treatment of Class III malocclusion.<sup>1</sup> The treatment protocol actually led to decompensation of the lingual tipping of the mandibular incisors usually observed in untreated Class III subjects.

The results of this study were obtained after active therapy. Longitudinal observations after fixed appliances and the pubertal growth spurt will be needed to assess the overall treatment changes in a longer term. The lateral cephalograms in this study were generated from 3-dimensional CBCT reconstructions. Future 3-dimensional assessments will provide a more comprehensive analysis of the modifications induced by the BAMP protocol.

## References

1. De Toffol L, Pavoni C, Baccetti T, Franchi L, Cozza P. Orthopedic treatment outcomes in Class III malocclusion. A systematic review. *Angle Orthod* 2008;78:561–73. [PubMed: 18416617]
2. Baccetti T, Franchi L, McNamara JA Jr. Treatment and posttreatment craniofacial changes after rapid maxillary expansion and face-mask therapy. *Am J Orthod Dentofacial Orthop* 2000;118:404–13. [PubMed: 11029736]
3. De Clerck HJ, Cornelis MA, Cevidanes LH, Heymann GC, Tulloch CJ. Orthopedic traction of the maxilla with miniplates: a new perspective for treatment of midface deficiency. *J Oral Maxillofac Surg* 2009;67:2123–9. [PubMed: 19761906]

4. Heymann GC, Cevidanes L, Cornelis M, De Clerck HJ, Tulloch JF. Three-dimensional analysis of maxillary protraction with intermaxillary elastics to miniplates. *Am J Orthod Dentofacial Orthop* 2010;137:274–84. [PubMed: 20152686]
5. Singer SL, Henry PJ, Rosenberg I. Osseointegrated implants as an adjunct to facemask therapy: a case report. *Angle Orthod* 2000;70:253–62. [PubMed: 10926436]
6. Enacar A, Giray B, Pehlivanoglu M, Iplikcioglu H. Facemask therapy with rigid anchorage in a patient with maxillary hypoplasia and severe oligodontia. *Am J Orthod Dentofacial Orthop* 2003;123:571–7. [PubMed: 12750679]
7. Hong H, Ngan P, Han G, Qi LG, Wei SH. Use of onplants as stable anchorage for facemask treatment: a case report. *Angle Orthod* 2005;75:453–60. [PubMed: 15898388]
8. Kircelli BH, Pektas ZO. Midfacial protraction with skeletally anchored face mask therapy: a novel approach and preliminary results. *Am J Orthod Dentofacial Orthop* 2008;133:440–9. [PubMed: 18331946]
9. Baccetti T, Franchi L, McNamara JA Jr. The cervical vertebral maturation (CVM) method for the assessment of optimal treatment timing in dentofacial orthopedics. *Semin Orthod* 2005;11:119–29.
10. Ludlow JB, Gubler M, Cevidanes L, Mol A. Precision of cephalometric landmark identification: cone-beam computed tomography vs conventional cephalometric views. *Am J Orthod Dentofacial Orthop* 2009;136:312.e1–10. [PubMed: 19732656]
11. Cevidanes L, Oliveira AEF, Motta A, Phillips C, Burke B, Tyndall D. Head orientation in CBCT-generated lateral cephalograms. *Angle Orthod* 2009;79:971–7. [PubMed: 19705941]



**Fig 1.**  
Position of the 4 bone anchors and intermaxillary elastics in the BAMP protocol.

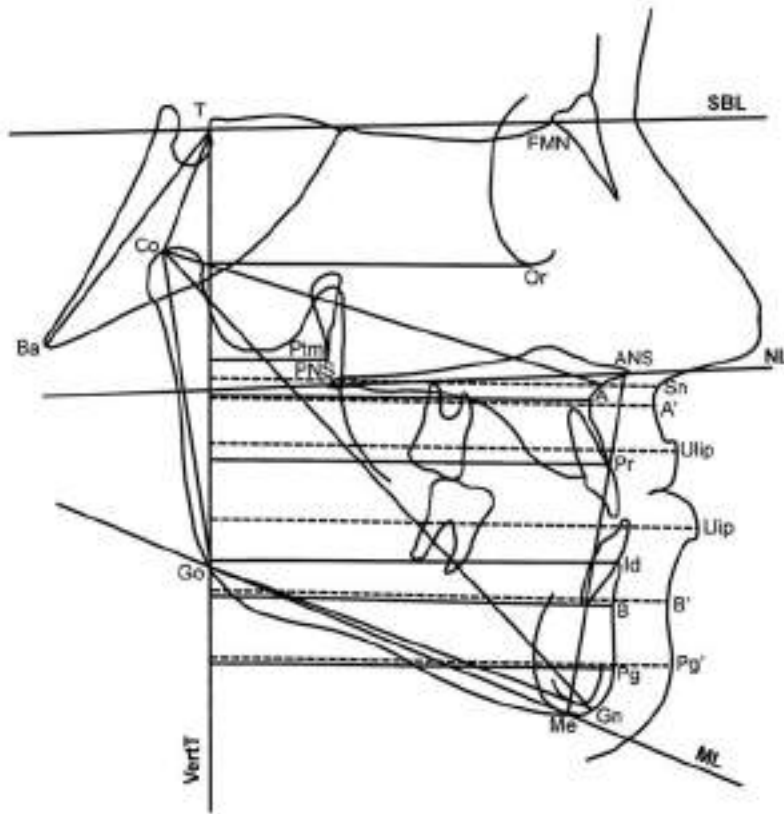


Fig 2.  
Skeletal and soft-tissue measurements.

Table 1

Descriptive statistics for starting forms at T1 and comparisons

	BAMP (n = 21)		Controls (n = 18)		Difference	t	Significance
	Mean	SD	Mean	SD			
A-VertT (mm)	63.9	4.1	63.3	3.9	+0.6	0.64	NS
Co-A (mm)	93.7	3.8	92.4	4.1	+1.3	0.32	NS
Ptm-VertT (mm)	13.8	3.2	12.9	3.4	+0.9	0.40	NS
Or-VertT (mm)	52.3	3.9	51.6	3.5	+0.7	0.56	NS
Pr-VertT (mm)	66.6	4.9	65.3	4.1	+1.3	0.38	NS
Id-VertT (mm)	65.7	6.6	66.9	5.5	-1.2	0.54	NS
B-VertT (mm)	61.9	6.7	62.5	5.6	-0.6	0.76	NS
Pg-VertT (mm)	61.5	7.2	62.6	6.5	-1.2	0.59	NS
Co-Gn (mm)	123.1	4.5	124.1	3.7	+1.3	0.34	NS
Co-Go (mm)	60.0	3.2	61.9	3.8	+1.9	0.04	*
Go-Gn (mm)	72.5	3.4	73.4	2.9	+0.9	0.44	NS
Wis (mm)	-4.8	2.8	-5.2	2.9	+0.4	0.43	NS
Mx-Md diff (mm)	29.8	4.1	31.7	3.9	-1.9	0.15	NS
Ba-T-VertT (°)	40.2	4.1	38.3	3.6	+1.9	0.14	NS
Co-T-VertT (°)	44.6	4.3	43.1	3.9	+1.5	0.21	NS
ML-SBL (°)	29.6	4.8	27.9	3.7	+1.7	0.22	NS
NL-SBL (°)	1.6	1.9	0.8	2.2	+0.8	0.23	NS
NL-ML (°)	27.9	4.3	27.2	3.4	+0.7	0.58	NS
Co-Go-Me (°)	128.9	3.3	127.2	3.8	+1.7	0.36	NS
ANS-Me (mm)	61.6	4.1	60.4	3.7	+1.2	0.54	NS
U1-NL (°)	112.4	6.2	114.4	5.1	-2.0	0.02	*
L1-ML (°)	88.5	4.0	87.0	4.2	+1.5	0.25	NS
Overjet (mm)	-1.0	2.1	-1.3	2.0	+0.3	0.65	NS
Overbite (mm)	1.3	1.6	2.2	1.9	-0.9	0.07	NS
Molrel (mm)	-5.2	1.5	-4.5	1.8	-0.7	0.24	NS
Sn-VertT (mm)	79.2	4.6	77.7	4.1	+1.5	0.29	NS
A-VertT (mm)	79.4	4.7	77.6	4.2	+1.8	0.32	NS
Ulup-VertT (mm)	82.3	5.2	80.9	5.4	+1.4	0.42	NS



	BAMP (n = 21)		Controls (n = 18)		t	Significance	
	Mean	SD	Mean	SD			
Llip-VertT (mm)	82.1	6.3	82.0	4.8	+0.1	0.95	NS
B'-VertT (mm)	75.7	6.5	76.6	4.6	-0.9	0.63	NS
Pg'-VertT (mm)	75.3	7.1	75.6	5.9	-0.3	0.88	NS
Age (y.mo)	11.10	1.8	11.6	1.7	+0.4	0.73	NS

BAMP group (10 girls, 11 boys); ages, 9.0–13.6 years at T1 and 10.0–14.6 years at T2. Untreated Class III controls (7 girls, 11 boys); ages, 8.8–13.1 years at T1 and at 9.8–14.2 years at T2.

\*  $P < 0.05$ ; NS, not significant.

Table II

Descriptive statistics for T1-T2 changes and comparisons

	BAMP (n = 21)			Controls (n = 18)			t	Significance
	Mean	SD	Mean	SD	Mean	SD		
A-VertT (mm)	5.2	1.9	1.3	1.4	+3.9	7.01	‡	
Co-A (mm)	5.3	2.0	1.5	1.6	+3.8	6.52	‡	
Ptm-VertT (mm)	2.6	1.3	0.8	0.4	+1.8	4.31	‡	
Or-VertT (mm)	3.5	1.3	0.6	0.5	+2.9	8.91	‡	
Pt-VertT (mm)	5.3	1.9	1.6	1.1	+3.7	7.07	‡	
Id-VertT (mm)	-4	1.8	2.1	1.5	-2.5	4.66	‡	
B-VertT (mm)	-6	2.0	2.2	1.6	-2.7	4.71	‡	
Pg-VertT (mm)	-6	2.3	2.2	1.5	-2.8	4.34	‡	
Co-Gn (mm)	2.1	1.7	4.1	2.2	-2.0	3.21	*	
Co-Go (mm)	1.7	1.2	2.1	1.8	-0.4	0.82	NS	
Go-Gn (mm)	1.8	1.3	2.6	2.0	-0.8	1.51	NS	
Wis (mm)	5.9	2.2	-0.8	1.7	+6.7	10.50	‡	
Mx-Md diff (mm)	-3.2	2.1	2.5	1.9	-5.7	8.83	‡	
Ba-T-VertT (°)	.1	.8	-3	0.6	+0.4	1.74	NS	
Co-T-VertT (°)	2.4	1.5	0.4	0.9	+2.0	4.94	‡	
ML-SBL (°)	-1.2	1.3	-0.2	0.7	-1.0	2.99	*	
NL-SBL (°)	-4	1.2	-0.6	1.2	+0.2	0.51	NS	
NL-ML (°)	-8	1.4	0.3	0.9	-1.1	3.02	*	
Co-Go-Me (°)	-2.6	1.3	1.5	2.8	-4.1	6.01	‡	
ANS-Me (mm)	1.0	1.6	1.7	1.5	-0.7	0.74	NS	
U1-NL (°)	.6	3.1	-0.1	2.1	+0.7	0.81	NS	
L1-ML (°)	1.9	1.6	0.2	2.2	+1.7	2.87	*	
Overjet (mm)	3.7	1.9	-0.1	0.6	+3.8	8.13	‡	
Overbite (mm)	1.4	1.8	-0.1	0.7	+1.5	3.32	*	
Molrel (mm)	4.6	1.8	-0.2	0.5	+4.8	10.98	‡	
Sn-VertT (mm)	5.4	2.0	1.5	2.2	+3.9	6.08	‡	
A'-VertT (mm)	5.8	2.3	1.4	2.5	+4.4	5.93	‡	
Ulipa-VertT (mm)	5.5	2.4	1.5	2.4	+4.0	5.45	‡	

	BAMP (n = 21)		Controls (n = 18)		t	Significance
	Mean	SD	Mean	SD		
Lip-VertT (mm)	.4	1.8	2.1	1.8	-1.7	2.94 *
B'-VertT (mm)	-.9	1.8	1.7	1.6	-2.6	4.73 †
Pg'-VertT (mm)	-.5	1.9	1.8	1.9	-2.3	3.77 †
Age (mo)	12.1	1.0	12.0	1.1	0.0	0.00 NS

\*  $P < 0.01$ ;

†  $P < 0.0001$ ;

‡  $P < 0.00001$ ; NS, not significant.